



Universitatea Națională  
de Știință și Tehnologie  
POLITEHNICA BUCUREȘTI

Școala Doctorală de Electronică, Telecomunicații  
și Tehnologia Informației  
Universitatea Națională de Știință și Tehnologie  
Politehnica din București

**Doctoral School of Electronics, Telecommunications  
and Information Technology**

Decision No. \_\_\_\_ from DD-MM-YYYY

# **Ph.D. THESIS SUMMARY**

**Silvia Ovreiu**

---

## **Retinal Image Analysis Using Deep Learning Algorithms**

---

### **THESIS COMMITTEE**

<b>Prof. Dr. Ing. Ion MARGHESCU</b> Politehnica Univ. of Bucharest	Președinte
<b>Prof. Dr. Ing. Mihai CIUC</b> Univ. Politehnica din București	Conducător de doctorat
<b>Conf. Dr. Ing. Alina SULTANA</b> Univ. Politehnica din București	Referent
<b>Prof. Dr. Ing. Liviu GORAȘ</b> Univ. Tehnică „Gheorghe Asachi” din Iași	Referent
<b>Prof. Dr. Ing. Cristian GRAVA</b> Universitatea din Oradea	Referent

**BUCUREȘTI 2023**

---



## Introduction

### Introduction to the Research Field

The doctoral thesis addresses a fundamental issue within the medical and artificial intelligence domain, focusing on the automatic detection of glaucoma from retinal images using deep learning algorithms. Glaucoma stands as one of the ocular conditions significantly impacting vision and overall eye health. The utilization of artificial intelligence and deep learning to detect glaucoma from retinal images represents an extremely promising research direction. These techniques enable a detailed analysis of data from images, identifying subtle features that could indicate the presence of glaucoma, even in its early stages.

Artificial intelligence (AI) represents the ability of computer systems to perform specific tasks traditionally requiring human intelligence intervention. These tasks include natural language understanding, pattern recognition, decision-making, and the ability to learn from experience. AI technology has gained momentum in recent decades, influenced by several factors contributing to the evolution and progress of this field. Among these factors are:

- a) **Computing Power:** Technological advancements in computing and data processing have facilitated the creation and management of enormous amounts of data. This has provided the groundwork for AI algorithms capable of learning from data and making decisions.
- b) **Data:** The exponential growth of available data has made the development of AI possible. With large diverse datasets, AI algorithms can learn complex models that would otherwise be difficult for programmers to explicitly create.
- c) **Resource Availability:** Advancements in hardware, such as graphics processing units (GPUs) and specialized accelerators, have dramatically increased processing capacity, enabling the training of AI models much more rapidly and efficiently.
- d) **Advanced Algorithms:** Progress in developing machine learning and deep learning algorithms has allowed the modeling and understanding of complex problems.

All these factors have created a conducive environment for the development of artificial intelligence and have led to remarkable progress in this field.

Machine learning involves manually extracting features from data and then analyzing these features using machine learning models such as support vector machines, random forests, etc. To create a high-performing model specialized for particular tasks, it requires training on a large amount of data (big data), which is now readily available. However, manually extracting features from this data becomes nearly impossible, making machine learning a method limited only to certain activities.

Instead, deep learning has emerged, a branch of machine learning that eliminates the need for manual feature extraction from data, thereby improving the efficiency of time and resources.

Bd. Iuliu Maniu nr. 1-3, ETTI corp A, 061071, București

Tel.: 021 402 48 67, 021 402 47 04

Email: [sdetti@upb.ro](mailto:sdetti@upb.ro)

Website: <http://www.sdetti.upb.ro/>, <https://upb.ro/>



Deep learning has proven to be more efficient than traditional machine learning in many domains, such as computer vision, natural language processing, and speech recognition.

Deep learning is implemented using neural networks organized into multiple layers, each layer consisting of a large number of interconnected neurons. This neuron-based structure is inspired by the human brain, where there are tens of millions of neurons and over 100,000 connections between these neurons. In deep learning, these networks are called artificial neural networks and consist of an input layer, an output layer, and several intermediate hidden layers. Deep learning utilizes a large number of layers of hidden neural networks, hence the name "deep" learning. Each layer can have a different number of neurons. Typically, the output layer has a number of neurons equal to the number of classes in which the data is desired to be classified, with each neuron representing the probability of belonging to a specific category.

The layers of neural networks are organized in a cascade, with the output of each layer becoming the input for the next. The training of a neural network relies on forward and backward propagation algorithms. Forward propagation refers to the entire process of propagating data from the input level to the output level, sequentially computing the intermediate variables of each neuron. Backward propagation optimizes the parameters of the neural network, starting from the intermediate variables of each neuron and utilizing gradient descent algorithms.

Through the connections between these layers and through nonlinear processing, the high-level network can automatically learn more abstract and generalized features from data, surpassing the need for manual feature extraction by machine learning models.

In the medical field, due to the advancements in medical technology, an increasing amount of data is being generated, forming the foundation of artificial intelligence. These large amounts of biomedical data contain efficient information for developing precision medicine or personalized medicine. Unlike large datasets in other fields, medical datasets are multidimensional, noisy, sparse, and mixed, making it challenging to extract relevant information from them. Deep learning plays a crucial role in successfully analyzing these large datasets and is considered the most advanced method of artificial intelligence. Medical imaging, electronic health records, genomics, and drug development are a few applications of deep learning in medicine.

One of the earliest applications of artificial intelligence in medicine is medical imaging. Thanks to increasingly sophisticated medical imaging equipment, medical imaging has become a widespread method used in diagnosis and treatment. Medical devices now generate a multitude of medical images, and analyzing them by experts becomes a costly activity. Furthermore, varying levels of expertise among physicians, as well as other factors like fatigue, can lead to diagnostic errors. Automated analysis of images using deep learning algorithms has become a tool that can assist specialists in making diagnoses. Deep learning is successfully applied in image classification, target recognition, and segmentation. Among all architectures of deep learning algorithms, convolutional neural networks are best suited for medical image analysis. Their convolutional layers have the potential to learn local features of



images. Identification of breast cancer, skin cancer, detection of pneumonia, retinopathy are a few applications of deep learning in medical imaging.

When it comes to eye imaging, analyzing retinal images has become one of the most important tools for eye analysis, as relevant eye information is found in the retina. Thus, machine learning algorithms are applied for classifying retinal diseases, segmenting retinal pathology, and identifying retina characteristics.

The fundus image of the eye usually reflects the inner surface of the eye and is obtained using image sensors. This image contains information about the biological structures of the retina, such as its surface, vascularization, macula, and optic disc. Images obtained from image sensors are typically in three colors: the blue color spectrum aids in visualizing the anterior layers of the retina, as blood vessels and the posterior layer of retinal pigment absorb the blue color, the green spectrum is reflected by retinal pigmentation, providing more information beneath the retinal surface, and the red spectrum is reflected solely by the choroidal layer under the pigmented epithelium and contains information about choroidal ruptures, choroidal nevi, choroidal melanomas, and pigmentary disorders.

The eye captures visual information in the form of light, which is focused through light-sensitive tissues. Retinal photoreceptors responding to specific spectral regions convert detected light information into electrical signals, which are then transmitted to the brain's visual cortex through nerve fibers. These signals are then interpreted as visual images in the brain.

The eye contains several biological landmarks. The macula is the region in the retina with a very high concentration of photoreceptors, providing maximum resolution. For this reason, the macula represents the central area of the retinal image. At the center of the macular region lies the fovea, responsible for high-acuity central vision. The optic disc, also known as the head of the optic nerve, is where nerve fibers converge before reaching the visual cortex. The optic disc is a circular area at the eye's fundus. Retinal blood vessels emanate from the optic disc and extend into the retinal layers. The retina comprises 7 layers, each containing different types of cells. Retinal vessels are classified based on their positions: superficial, intermediate, and deep vessels. These are situated in the nerve fiber layer along the lateral parts of the inner nuclear layers. Subsequently, the choroidal vessels are located beneath the retinal pigment epithelium and Bruch's membrane. These vessels supply nutrients and oxygen to the photoreceptors.

There are several changes in the retina's structure, known as retinopathies, that lead to vision impairment. Among the most common retinopathies are diabetic retinopathy (DR), age-related macular degeneration (AMD), and glaucoma.

DR is a problem caused by abnormal blood flow and is triggered by diabetes, which affects blood flow due to either excessively low or high sugar levels in blood vessels. As a result, retinal lesions may occur, such as microaneurysms, cotton wool spots, hemorrhages, exudates, and neovascularization.



AMD is caused by the aging of retinal tissue and is the primary cause of blindness in the elderly worldwide.

Glaucoma affects the optic nerve and ganglion cells, caused by increased intraocular pressure. There are two types of glaucoma: angle-closure and open-angle. The pressure inside the eye is controlled by a fluid called aqueous humor. This fluid is produced behind the iris and exits through the trabecular meshwork. When the outflow rate of this fluid is lower than its production rate, it results in high pressure, affecting the optic nerve behind the eye. The condition caused by the drainage problem due to the trabecular meshwork is called open-angle glaucoma. When the meshwork gets blocked, the condition is called angle-closure glaucoma. There is also a situation where glaucoma occurs even when the intraocular pressure is normal. This is called normal-tension glaucoma and can only be diagnosed through signs of optic nerve damage.

When it comes to analyzing retinal images, machine learning algorithms, including deep learning, yield excellent results for applications such as identifying and segmenting retinal blood vessels in fundus images, as well as automatically classifying them. Retinal blood vessels have a complex structure, with bifurcations, intersections, and abrupt interruptions, making their segmentation quite challenging.

Another application of deep learning algorithms is the automatic classification of retinal images, which is a highly useful method for medical screening. Automatic image classification is a much more complex task than identifying and segmenting retinal features and then classifying them. Consequently, deep learning algorithms yield much better results in these situations than traditional machine learning methods.

This thesis endeavors to explore the intersection between medicine and technology, contributing to the development of powerful tools for diagnosing and treating glaucoma and, by extension, advancing personalized medicine and healthcare.

This research represents an innovative approach to disease diagnosis, leveraging the power of deep learning technologies to analyze retinal images precisely and efficiently. The thesis aims to develop and evaluate advanced algorithms capable of identifying early signs of glaucoma in retinal images with high accuracy and without involving invasive or costly procedures.

One of the major issues with glaucoma is its progressive and slow development. This means that individuals with glaucoma are often diagnosed, due to lack of symptoms, in a late stage of the disease, where they might have already lost up to 70% of their vision. Furthermore, vision loss caused by glaucoma is irreversible, making early diagnosis crucial to start treatment and slow down or even halt the progression of the disease.

An automated method for diagnosing glaucoma, especially in its early stages when retinal changes are difficult to observe with the naked eye, is a valuable tool for both population screening and diagnosing the onset of glaucoma. This thesis explores various models of deep learning algorithms for the automatic diagnosis of glaucoma from fundus images, including diagnosing it in the early stages when retinal changes are imperceptible.



By integrating deep learning technologies into glaucoma diagnosis, this thesis proposes a modern and scalable method that could revolutionize how eye conditions are identified and treated. While traditional methods require human expertise and considerable time for image analysis, deep learning algorithms can analyze and interpret data with impressive speed and precision.

This doctoral thesis represents a comprehensive exploration of automatic glaucoma diagnosis from retinal images, focusing on the use of deep learning algorithms. Structured into seven distinct chapters, this work brings to the forefront an interdisciplinary approach that combines knowledge from human eye anatomy and functionality, artificial intelligence technologies, and the medical field.

Chapter 2 details the structure and functionality of the human eye, including essential anatomical aspects for a further understanding of glaucoma. Information regarding glaucoma, including its causes, types, and changes occurring in the eye, is also addressed. Additionally, the chapter provides an overview of deep learning algorithms, as well as their types and applications in the medical field, particularly in glaucoma diagnosis.

Chapter 3 presents the current state of automatic glaucoma diagnosis from retinal images. This section provides a comprehensive overview of the current state of automatic glaucoma diagnosis from retinal images. The methods and techniques used in the specialized literature are discussed, highlighting their advantages and challenges.

Chapter 4 represents the author's first contribution, presenting an approach for diagnosing glaucoma in very early stages. This approach is based on the ResNet neural network architecture and emphasizes the results obtained using this methodology.

Chapter 5 aims to evaluate and compare the results obtained using two variants of the DenseNet architecture (DenseNet 121 and DenseNet 201). Through the analysis of these results, the goal is to identify the most efficient approach in diagnosing early-stage glaucoma.

In the final chapter, the thesis draws the final conclusions, synthesizing the results obtained and the contributions made. Additionally, the implications of the results for the medical field are discussed, and future research directions are outlined.

Furthermore, recent progress and innovations in the field are analyzed, focusing on how these technologies can contribute to the early and accurate detection of glaucoma. The various types of artificial neural networks, such as CNN, as well as other deep learning models for analyzing imaging data, will be examined. Different databases of glaucoma images used in literature to train and validate developed algorithms will be presented.

We will discuss the advantages and disadvantages of each examined model, as well as the obtained results. Additionally, we will address the challenges and future perspectives in this continually evolving field. These insights can contribute to a better understanding of the potential of DL algorithms in enhancing the diagnosis and management of glaucoma.

This section presents the main public and private image databases that have been recently used to evaluate the performance of algorithms in literature. The databases include either





images with glaucoma alone or images with multiple pathologies. Both public and private databases will be presented. Further, both public and private databases used in my doctoral work will be introduced.

The ACRIMA dataset was the focus of a project funded by the Ministry of Economy in Spain. The database contains 705 images, out of which 396 depict glaucoma and 309 are normal. The images were obtained using the Topcon TRC fundus camera, from both left and right eyes, which were dilated beforehand. Image annotation was performed by two glaucoma experts with 8 years of experience. No other clinical information was considered in diagnosing glaucoma from these images. According to the article where this image base was first published, the database can only be used for glaucoma classification.

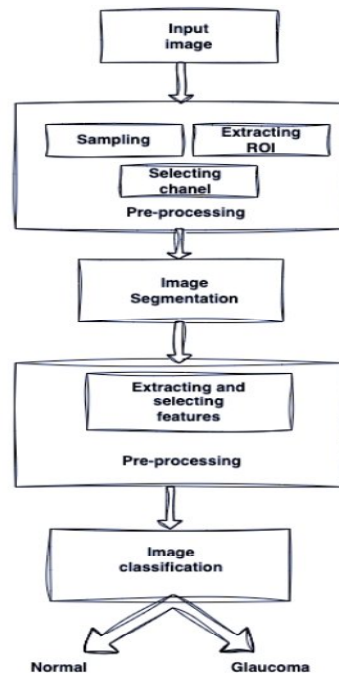
The Online Retinal Images for Glaucoma Analysis (ORIGA) is one of the largest retinal image datasets used for glaucoma detection. It has been used as a standard dataset in various recent studies. The dataset was obtained from the Singapore Eye Research Center and comprised 650 images (168 from glaucoma-affected individuals and 482 from healthy individuals). Each image has a resolution of  $3072 \times 2048$  pixels. Besides fundus images, it provides manual segmentation of the optic disc and cup for all images. The images were collected between 2004 and 2007 and annotated by well-trained professionals. The subjects in this study were aged between 40 and 80 years.

The High-Resolution Fundus (HRF) dataset was made public in 2013 and includes 45 images divided into 3 classes of 15 images each: 15 healthy eye images, 15 images from patients with diabetic retinopathy, and 15 images from patients with glaucoma. Each image's size is  $3304 \times 2336$  pixels. It is a dataset used for retinal blood vessel segmentation.

The Retinal Images for Optic Nerve Evaluation (RIM-ONE) dataset consists of 169 fundus images, each with a resolution of  $2144 \times 1424$  pixels. All images have annotations of the optic cup and disc. The images were captured using a Nidek AFC-210 fundus camera. Following diagnosis by specialists, the images were classified into the following categories: 118 images from normal eyes (without glaucoma), 12 images with early-stage glaucoma, 14 images with moderate-stage glaucoma, 14 images with advanced glaucoma, and 11 images from patients with ocular hypertension. The images were obtained from three Spanish hospitals.

The Drishti-GS dataset contains 101 images, divided into 70 glaucoma images and 31 healthy images. The images were collected at the Aravind Eye Hospital, Madurai, India. All images were obtained with prior eye dilation, centered on the optic disc, and have a resolution of  $2896 \times 1944$  pixels. The images were evaluated by four experts with 3, 5, 9, and 20 years of experience. The images were segmented around the optic disc head.

The Singapore Chinese Eye Study Ophthalmology (SCES) dataset was created in a screening study and comprises 1676 images, including 1630 normal images and 46 glaucoma images. This private database contains images with resolutions of  $3888 \times 2592$  and  $3504 \times 2336$  pixels. It is a private dataset available upon request.



**Figura 1. 1** *Procesul de detectare a glaucomului*

The process of glaucoma detection based on feature extraction is presented in Figure 1.1 and involves the processing of the input image, including steps such as sampling, identifying the region of interest (ROI), and selecting the appropriate channel. Subsequently, the image is segmented to highlight relevant features (retinal vessels, optic disc), which are then extracted and segmented. Based on these segmentations, the classification of retinal images is conducted, differentiating between normal and glaucomatous conditions.

Relevant elements in the retina aiding in diagnosis are the optic disc, vascular bundles, or blood vessels. Therefore, segmenting these characteristic retinal elements is an extremely crucial step, as correct identification from these features leads to accurate image diagnosis.

An article proposes a method for glaucoma detection from retinal images acquired at the Department of Ophthalmology, KMC, Manipal, India. A total of 272 retinal images (100 normal, 72 with mild glaucoma, and 100 with moderate-severe glaucoma) were obtained initially with a resolution of  $2588 \times 1958$ , which was later reduced to  $740 \times 576$  to expedite computation. The images were preprocessed for uniformity. They were then decomposed through Radon transformation. The resulting projections were utilized for calculating high-order statistical moments, resulting in cumulant high-order features. Dimensionality reduction was performed using Principal Component Analysis (PCA), Independent Component Analysis (ICA), and Linear Discriminant Analysis (LDA). It was observed that LDA exhibited the highest classification accuracy. These results were integrated into a method employing Fisher's discriminant index. Machine learning models such as SVM and Naïve

Bd. Iuliu Maniu nr. 1-3, ETTI corp A, 061071, București

Tel.: 021 402 48 67, 021 402 47 04

Email: [sdetti@upb.ro](mailto:sdetti@upb.ro)

Website: <http://www.sdetti.upb.ro/>, <https://upb.ro/>





Bayes were used for image classification, resulting in an average accuracy of 84.72% for mild glaucoma detection and 92.65% accuracy across all three classes, based on the Naïve Bayes classifier.

Another classification method was developed adopting a fuzzy logic-based approach. Images were initially processed to eliminate noise using appropriate filters, and the Canny edge detection algorithm was utilized for contour extraction. After identifying the elliptical shapes of the optic disc and excavations, key parameters were extracted using Randomized Hough Transform. Classification was performed using fuzzy logic. Additionally, the method considered various parameters and risk factors such as age, race, family history, among others, making it more valuable for identifying glaucoma cases. The algorithm was tested on real images, yielding results indicating over 96% accuracy. However, the authors did not present the dataset on which the algorithm was trained, mentioning only that it was tested on real datasets. The number and quality of these datasets, however, were not specified.

In another article, a different cup and optic disc segmentation method are presented. The approach used an iterative linear simple clustering of superpixels to group pixels in the image. The linear simple segmentation algorithm was applied to create superpixels, subsequently utilized for extracting image characteristics based on histogram data and texture information.

These features were then input into an SVM algorithm for classification, assigning each superpixel to categories such as optic disc, optic cup, blood vessel, and other background regions. Glaucoma identification in retinal images relied on measurements of the cup-to-disc ratio (CDR), achieving an average precision of 98.6%.

Another category of algorithms employs CNNs for automatic classification of glaucoma from fundus images. Hence, both feature extraction from images and their classification are performed automatically in a single step. Typically, two approaches are used: either the network is trained from scratch, or transfer learning is employed, where a network pre-trained on a larger dataset like ImageNet is used. This approach is applied when datasets for training networks are insufficiently large.

The algorithms in this category are classified into two classes: the first class detects glaucoma from 2D retinal images captured by digital fundus cameras, and the second category detects from 3D images obtained using OCT. We will now present algorithms from the first category. One of the early attempts at automatic glaucoma detection using a deep convolutional neural network is presented in an article. Authors utilized a six-layer CNN architecture to distinguish between glaucomatous and non-glaucomatous cases. The model was trained from scratch using images with the region of interest centered around the optic disc, extracted from two public datasets. The results showed an AUC of 0.887. In another study [74], an 18-layer CNN, along with an LDA classifier, was trained for glaucoma classification using a dataset comprising 1426 fundus images obtained from Kasturba Medical College, Manipal, India. The achieved accuracy was 98.13%.

Regarding the current state of automated glaucoma detection methods, we can summarize the following:



- 1) Convolutional Neural Networks (CNNs) have become highly efficient for glaucoma detection from fundus images. They have been employed in various approaches, including optic disc and cup segmentation, glaucoma classification, and differentiating between disease stages.
- 2) There are two main categories of CNN algorithms for glaucoma detection. The first category uses CNNs to extract features from images, subsequently used to train classifiers such as Support Vector Machines or Decision Trees. The second category employs CNNs for direct image classification without manual feature extraction.
- 3) Many researchers have proposed and evaluated various CNN architectures such as VGG, ResNet, Inception, among others, for glaucoma detection. These architectures have demonstrated good performance across different datasets.
- 4) Several studies have addressed glaucoma detection in early stages, which poses a significant challenge in diagnosing this disease.
- 5) Combined methods, using both CNNs and other techniques like Gabor transformation or wavelet features, have also shown promising performances in glaucoma detection.
- 6) It is important to note that algorithm performance may vary depending on the dataset used for training and testing, and cross-validation has often been used to evaluate the results.
- 7) Different types of images have been used for glaucoma detection: fundus images, OCT, and OCT-A.

Recent research in glaucoma detection using CNNs demonstrates the promise of this approach for disease diagnosis and screening. However, more efforts are needed to develop and validate robust algorithms usable in clinical practice for early and accurate glaucoma detection.

In the first part of the doctoral research, we applied a residual network model to a dataset consisting of color fundus images, including both images from subjects with early-stage glaucoma and those with advanced glaucoma. We demonstrated that by applying a residual network, we can diagnose glaucoma with an accuracy level of 96.97%. This is a promising indicator that convolutional neural networks have significant potential to become a tool for early glaucoma detection.

Therefore, the complex procedure used today for diagnosing early-stage glaucoma could potentially be replaced by a computer-assisted diagnostic system that utilizes deep learning algorithms. In conclusion, the use of residual networks in early glaucoma detection represents a promising and innovative approach in the field of ophthalmology. This advanced deep learning technique enables the identification of early signs of glaucoma in fundus images, facilitating prompt interventions and appropriate treatment.

By utilizing residual networks, precise and generalizable results can be obtained, allowing for the detection of glaucoma in its early stages. This provides an opportunity to intervene before optic nerve damage becomes irreversible, thereby contributing to improving the prognosis and quality of life for patients.

It is important to note that the results obtained through residual networks should be interpreted in the context of clinical evaluation performed by specialist ophthalmologists.



These advanced techniques serve as complementary tools that can support the diagnostic process and decision-making but should not replace medical expertise.

Furthermore, research and development in this field can contribute to refining early glaucoma detection techniques and integrating them into current medical practice. The use of residual networks in early glaucoma detection represents an important step toward improving the management and treatment of this serious eye condition.

In the second part of the thesis, glaucoma, one of the most damaging eye diseases that can cause asymptomatic blindness, is presented. It needs to be diagnosed as early as possible for patients with these conditions.

DL models have proven to be efficient in supporting this early diagnosis. By using Convolutional Neural Networks (CNNs) and DenseNet architecture, promising results can be achieved in glaucoma detection from fundus images. DenseNet stands out due to its dense connectivity, allowing direct information propagation and learning features at different levels of the network. This aspect can enhance the model's ability to capture complex features and make more precise distinctions between normal and glaucomatous images.

Studies and research have demonstrated that using DenseNet architecture in glaucoma detection can achieve remarkable performance in terms of accuracy, sensitivity, and specificity. The DenseNet model can be trained on large and diverse datasets, contributing to generalization and the ability to handle variations in images.

However, it is important to consider other aspects in implementing and utilizing the DenseNet model in clinical practice. These include proper selection and preparation of datasets, image preprocessing, model hyperparameter tuning, and validation of obtained results.

In conclusion, the use of DL techniques and DenseNet architecture in glaucoma detection based on digital fundus images represents a promising and efficient approach. This method can contribute to the early diagnosis of glaucoma and improve healthcare for patients affected by this ocular condition. However, continued research and development in this field are crucial to validate and enhance the performance and practical use of DenseNet models in glaucoma detection.

In conclusion, this doctoral thesis addresses the possibility of automating the diagnosis of glaucoma using machine learning algorithms. According to the World Health Organization, glaucoma is the second leading cause of irreversible blindness globally, following cataracts. Furthermore, glaucoma is asymptomatic, often diagnosed only after the patient has already lost up to 70% of their vision. Additionally, diagnosing glaucoma is a laborious process that involves using multiple analysis methods and advanced medical expertise. These factors make widespread population screening for glaucoma diagnosis extremely challenging to implement. Moreover, diagnosing glaucoma in its early stages, when retinal lesions caused by glaucoma are imperceptible, is even more challenging.

In this chapter, to accurately classify between glaucomatous and non-glaucomatous retinal images, the DenseNet network with 121 layers was trained on retina images cropped around the optic nerve head and its surrounding area, each image having dimensions of 224 x 224 x



3. Similar to the first model, this network was initially pre-trained on the ImageNet dataset. Subsequently, the network was trained on a fundus image database formed by amalgamating the RETINA database with public databases ACRIMA and RIM-ONE. After training the network on these images, after 50 epochs, an accuracy of 0.9563 and a loss function value of 0.1594 were achieved.

Specifically, the confusion matrix showed that 82 images were classified as healthy subjects (81 true positives and 1 false negative), and 88 were classified as patients suffering from glaucoma (84 true negatives and 4 false negatives). The sensitivity value was 0.952, and the specificity was 0.988. The obtained F1 score was 0.97. Only for images from the RETINA database, containing retinal images affected by early-stage glaucoma, where changes in retinal vascularization are extremely subtle, the DenseNet121 network managed to classify fairly well between the two classes, glaucoma and non-glaucoma, achieving an AUC value of 0.971.

From the results obtained with the ResNet network with 50 layers and those obtained with the DenseNet network with 121 layers, it can be observed that the DenseNet reached an accuracy of 0.95 much faster than ResNet, after approximately 50 epochs, while DenseNet achieved a similar accuracy after 200 epochs. Additionally, the DenseNet model had better results in diagnosing early-stage glaucoma images. Regarding the F1 score obtained with DenseNet, it was higher than the one obtained with ResNet (0.97 vs. 0.79). This implies that DenseNet is better at correctly classifying glaucomatous images compared to healthy ones than ResNet.

In Chapter 6, on the same set of images used in the previous chapters, the DenseNet network with 201 layers was trained. The network was pre-trained on the ImageNet dataset. After training for 200 epochs, a precision of 0.97 and an F1 score with a value of 0.969 were achieved. According to the confusion matrix, out of 85 retinal images from healthy subjects, 81 were correctly classified by the DenseNet121 network, and 4 were misclassified as coming from subjects with glaucoma. Similarly, out of the 85 retinal images from subjects with glaucoma, 84 were correctly diagnosed, and only 1 was diagnosed as normal.

The results indicate a fairly good capacity for correctly diagnosing glaucomatous versus non-glaucomatous images in the DenseNet201 network. Although one might expect significantly better results from DenseNet201, being deeper, the accuracy results are similar. The DenseNet201 network could not achieve an accuracy higher than 0.97 even after 200 epochs of training. Considering both networks were trained on a very small dataset, the limitation in accuracy comes from the training dataset. However, the DenseNet201 network obtained better results in correctly classifying glaucomatous images compared to DenseNet121, and both models achieved significantly better results than ResNet50.

From the results obtained above, we conclude that for a small dataset, a very deep network (e.g., 201 layers) does not significantly outperform a deep network (e.g., 121 layers). The difference would likely be noticeable only when working with a large dataset, comprising diverse images at different stages of glaucoma.

As a perspective for further development, we aim to diagnose glaucoma by analyzing its structural changes in the retina. For this purpose, we will introduce a dataset containing 3D images obtained using Optical Coherence Tomography (OCT). Additionally, to better



visualize glaucoma-related changes in retinal vasculature, images obtained through OCT Angiography (OCTA) will be used. We aim to analyze these images using deep learning algorithms in multiple scenarios: training algorithms on unimodal datasets (only OCT or OCTA images) or training on multimodal images (a combination of OCT, OCTA, and digital fundus images). This approach aims to accurately identify glaucoma-related changes, even in the early stages. Moreover, structural changes within retinal layers will also be examined, potentially revealing which changes manifest first at the onset of the disease (whether it is primarily affecting blood vessels or structural alterations).

In the current study, considering that glaucoma predominantly affects the optic nerve head and its vicinity, the images used for algorithm training were cropped around this region. In the future, we aim to validate this theory and assess if there are signs of glaucoma elsewhere in the retina. To accomplish this, the deep learning algorithm models will be trained on retinal images containing the entire retina except for the optic nerve head.

Furthermore, we aim to expand the database, including more images of retinas affected by early-stage glaucoma. We intend to train algorithms not only for binary classification (glaucoma versus non-glaucoma) but also for classifying glaucoma into multiple stages of disease progression.

In the current study, only images of glaucomatous patients without any additional pathologies were examined. Future developments involve including retinal images from patients with multiple pathologies like diabetes, cataracts, high blood pressure, etc. Algorithms trained using deep learning will be designed to recognize glaucoma-specific alterations in the retina, even if the retina is affected by other pathologies like diabetic retinopathy. Identifying glaucoma's characteristics and its specific effects on the retina when the retina is affected by other diseases is a research area that could lead to developing treatments for glaucoma.

Long-term goals include developing a robust solution capable of diagnosing not only glaucoma but multiple eye-related pathologies. Initially, such software would function as a screening tool, referring suspected cases for detailed diagnosis. Over time, such software could evolve into a diagnostic tool, providing direct diagnosis. Such a solution has the potential not only to facilitate rapid, accurate, and automatic eye disease diagnosis but also to grant access to such tests, particularly for patients with limited access to experienced ophthalmologists or medical centers.

These are just a few future research directions in analyzing retinal images using DL algorithms. Advancements in these areas could bring significant benefits to the medical field, enhancing the diagnosis and treatment of ocular conditions.